

A Familial Case of Multicentric Carpotarsal Osteolysis Syndrome and Treatment Outcome

Jariya Upadia¹ Alicia Gomes¹ Peter Weiser² Maria Descartes¹

¹Department of Genetics, University of Alabama at Birmingham, Birmingham, Alabama, United States

²Department of Pediatrics, University of Alabama at Birmingham, Alabama, United States

Address for correspondence Jariya Upadia, MD, Department of Genetics, University of Alabama at Birmingham, Birmingham, AL 35294, United States

(e-mail: jupadia@uabmc.edu; kae_jariya@hotmail.com).

J Pediatr Genet 2018;7:174–179.

Abstract

Multicentric carpotarsal osteolysis syndrome (MCTO) is a rare skeletal disorder caused by heterozygous mutations in the *MAFB* gene (v-maf musculoaponeurotic fibrosarcoma oncogene ortholog B). This is an autosomal dominant condition with a high frequency of sporadic cases. MCTO is characterized by osteolysis of the carpal, metacarpal, and tarsal bones beginning in early childhood with musculoskeletal rheumatologic symptoms such as pain and disability. Renal involvement can be seen in more than half of the patients; from ages 16 months to 42 years and manifests from proteinuria to end-stage renal failure requiring renal transplantation. The association of *MAFB* gene mutations with this genetic condition has aided in understanding the pathophysiology of the disease. We report here a 7-year-old Caucasian boy and his 33-year-old mother diagnosed with MCTO, with the boy having concomitant juvenile idiopathic arthritis. He was initially diagnosed with arthritis at age 5 years based on bilateral wrist synovial swelling, morning stiffness, and weakness with family history of his mother being diagnosed with erosive psoriatic arthritis leading to limb deformities. Initial therapy for the boy included methotrexate and infliximab with moderate response. Later, during the course of his disease, he underwent a genetic evaluation at age 7 years for history of learning disabilities and dysmorphic features. Maternal evaluation and radiographic examination led to a clinical diagnosis of MCTO in the mother, and subsequent testing for *MAFB* gene in the son revealed a mutation at c.206C > T (p.Ser69Leu), the most commonly reported genetic change in MCTO. Nevertheless, further imaging still confirmed ongoing arthritis, and therapy was adjusted based on its progression including abatacept, tocilizumab, and pamidronate. Our report highlights the possibility of concomitant inflammatory arthropathy in MCTO.

Keywords

- ▶ osteolysis
- ▶ nephropathy
- ▶ osteoclast
- ▶ inflammatory process

Introduction

Multicentric carpotarsal osteolysis (MCTO MIM#166300), with or without nephropathy, is a rare genetic disorder manifesting in early childhood as progressive destruction and disappearance of the carpal and tarsal bones.¹ Clinical manifestations present as aggressive osteolysis, especially of the carpal and tarsal bones; nephropathy; and craniofacial

anomalies. MCTO is an autosomal dominant disorder caused by mutations in the *MAFB* gene (v-maf musculoaponeurotic fibrosarcoma oncogene ortholog B) (MIM#608968) with a high frequency of sporadic cases. All mutations that have been reported cluster within a narrow region of a single exon in the amino-terminal transcription activation domain between amino acids 54 to 71.² Zankl et al found heterozygous missense mutations within this single exon of *MAFB*

received

May 23, 2017

accepted after revision

April 26, 2018

published online

June 16, 2018

Copyright © 2018 by Georg Thieme
Verlag KG, Stuttgart · New York

DOI <https://doi.org/10.1055/s-0038-1657760>.
ISSN 2146-4596.

in five unrelated simplex cases diagnosed with MCTO through whole exome sequencing with Sanger sequencing confirmation. In addition, six additional simplex cases with MCTO were also found to have heterozygous missense mutations in the same region of *MAFB* gene by Sanger sequencing.

MafB protein is encoded by the *MAFB* gene and regulates various developmental processes. MafB is essential for the inhibition of osteoclastogenesis. MafB negatively regulates a receptor activator of nuclear factor- κ B ligand (RANKL)-induced osteoclastogenesis by interfering with the DNA-binding domain of transcription factors, which are known to be important for osteoclast formation.³ Reduced MafB expression or RANKL stimulation causes overproduction of osteoclasts and results in excessive bone absorption. Nevertheless, the mechanism of predominantly affecting carpal and tarsal bones is still unclear. In addition, MafB is also expressed in glomerular epithelial cells (podocytes) and is essential for podocyte differentiation and renal tubule survival.⁴ Disruption of the *MAFB* gene can cause renal dysgenesis and tubular epithelial cell death.⁵

Clinical manifestations of MCTO begin in early childhood with arthritis-like episodes with variable phenotypic features and course. Reported clinical features include triangular shape of the face, chubby cheeks, protruding eyes, and micrognathia. Nephropathy has been reported but ranges significantly in severity,^{6,7} from mild proteinuria to a progressive nephropathy leading to end-stage-renal disease. In some cases the nephropathy can result from arteriolar thickening.^{8,9} The glomerular and interstitial pathological findings are nonspecific; focal segmental glomerulosclerosis has been documented.^{4,10}

Additional findings also include corneal clouding; however, the pathogenic mechanism of this ocular sign is unclear.^{4,7,11,12} Malecha and Wilroy reported corneal opacity in a 17-year-old female with MCTO, but her vision was not affected.¹¹ Mumm et al also reported three individuals found to have corneal opacity but no information regarding the progression of corneal clouding was provided.⁷ Shinohara et al reported a 5-year-old girl with bilateral peripheral corneal opacity in addition to osteolysis and glomerulonephropathy.⁴

While only one gene has been associated with this condition thus far, there has been significant interfamilial and intrafamilial clinical variability observed.^{1,7} Mehawej et al reported a 22-year-old severely affected male with MCTO presenting with carpal and tarsal bone involvement as well as involvement of the knee and thoracic vertebrae.¹ His presentation required surgical intervention and extensive physical therapy, while his affected father presents with milder orthopedic involvement.¹ There is also evidence of incomplete penetrance in one family; an affected male was found to have an *MAFB* mutation (c.167C > T, p.Ser56Phe) while three generations of family members including his mother, maternal grandmother, and sister harbor the same alteration but were noted to be asymptomatic.¹³

To date, twenty-four simplex cases and six familial cases with MCTO have been reported to have mutations in *MAFB* gene since the *MAFB* gene was first identified in 2012.^{1,2,7,13,14} The most common mutations found in simplex cases are c.206C > T (p.Ser69Leu) and c.176C > T (Pro59Leu). Seven patients have been reported to share the c.206C > T (p.Ser69Leu) mutation including our case (→ **Table 1**).

Table 1 Clinical characteristics of MCTO patients who share the same heterozygous missense mutation of *MAFB* gene identified in our proband: c.206C > T (p.Ser69Leu)

Patient	Case 1	Case 2	Case 3	Case 4	Case 5 (mother of patient 4)	Present case (son)	Present case (mother)
Onset of symptoms	2.5 years	Not known (JIA at age 6 years)	12 months	20 months	3 years	4 years	5 years
Age at MCTO diagnosis	14 years	11 years	6.5 years	5.5 years	38 years	7.5 years	33 years
Joint(s) affected	Elbows	Elbows	Elbows	Elbows	Wrists	Wrists	Wrists, elbows, feet
Renal findings	Proteinuria (7 years) Renal transplant (17 years)	Proteinuria (14 years)	None	None	Renal failure, shrunk kidney	None	NA
Eye	None	None	Corneal clouding	None	None	None	NA
Other	NA	NA	NA	NA	NA	Learning disability Hearing impairment	Learning disability

Abbreviations: JIA, juvenile idiopathic arthritis; MCTO, multicentric carpotarsal osteolysis syndrome; NA, not available.

Case Report

The proband is a 7.5-year-old Caucasian boy born to a 26-year-old, gravida 1 mother with a history of joint and bone disease with unclear etiology (she recalls being diagnosed with psoriatic arthritis). His early developmental history is significant for speech delay and delayed walking. In addition, he was found to have conductive hearing impairment in the left ear due to recurrent middle ear infections. He has a history of a learning disability. At 5 years of age, he was referred for a genetics evaluation. He was noted to have dysmorphic features including a prominent forehead, maxillary hypoplasia, and bilateral palpebral ptosis as well as a long philtrum and bulbous nose. Array comparative genomic hybridization was sent at that time and resulted as normal.

During the following year, he was seen at the pediatric rheumatology clinic and diagnosed with antinuclear antibody-positive polyarticular juvenile idiopathic arthritis based on history and physical exam including pain in both wrists and the bottom of his right foot with morning stiffness lasting 15 to 20 minutes with worsening during cold weather, nail pits, and arthritis of right temporomandibular joint, wrists, and proximal interphalangeal (PIP) joints of third to fourth fingers. Laboratory workup showed mild elevation of the erythrocyte sedimentation rate, negative human leukocyte antigen B27, and positive antinuclear antibody. Radiographic examination of the wrists showed deficiency of the carpal bones (►Fig. 1) with some erosive changes with osteopenia, nevertheless no lytic destructive lesions were seen on radiographs of the feet. During the course of his disease, he was treated with methotrexate and various biologics due to functional hand deficits, worsening joint contractures, and also due to the fact that repeated imaging by magnetic resonance imaging (MRI) was suggestive of ongoing and/or worsening synovitis and arthritis. Biologics included etanercept, infliximab, abatacept, and tocilizumab over the course of several years. At his last visit,

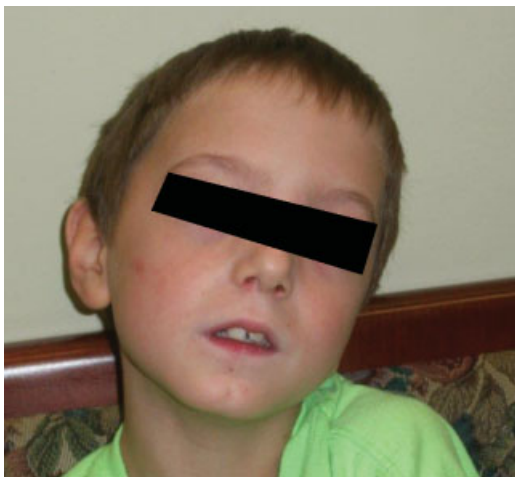

Fig. 1 Anteroposterior view of the patient at age 7 showing triangular face, exophthalmos, downslanting palpebral fissures, slim nose, small mouth, downturned corners of the mouth, and micrognathia.

he was switched to adalimumab, a monoclonal tumor necrosis factor (TNF) blocking antibody.

While being treated for arthritis, at the age of 7.5 years, he was seen in follow-up for a genetics evaluation. His physical examination was significant for joint deformities and more pronounced facial dysmorphisms that included triangular face, exophthalmos, downslanting palpebral fissures, small nares, small mouth, downturned corners of the mouth, and micrognathia (►Fig. 2). Age-based growth parameters, at age 7.5 years, showed height at the 37th percentile (124.9 cm), weight at the 7th percentile (20.6 kg), and head circumference at 75th percentile (53cm). Renal function was normal at this time. The pronounced facial dysmorphisms lead to the clinical diagnosis of MCTO. After informed consent was obtained for *MAFB* gene analysis, an ethylenediamine tetraacetic acid blood sample was collected. The *MAFB* gene was analyzed by polymerase chain reaction and Sanger sequencing of both DNA strands for the entire coding region as well as highly conserved exon-intron splice junctions. The reference sequence of the *MAFB* gene used is NM_005461.3. *MAFB* gene sequencing analysis revealed a heterozygous missense mutation at c.206C > T (p.Ser69Leu). This mutation is located in a short region of the amino-terminal transcriptional activation domain of *MAFB* gene.

Mother

Patient's mother is a 33-year-old Caucasian with a medical history of chronic joint pain and joint deformities. She started having pain in her wrists and elbows at age 5 years similar to her son. In late childhood, she started having pain in both wrists and in the bottom of both feet. She started developing abnormalities of the wrists, elbows, and feet during late childhood and adolescence and was diagnosed with erosive arthritis. She also reports a history of developmental delays.

Examination of the mother showed normal height. Her height was at the 60th percentile (165 cm). Her physical examination notes wide set eyes, triangular face, small and thick ears, hypoplastic nares, bulbous tip of the nose, and micrognathia (►Fig. 3A). She had shortening of the distal upper limb and ulnar deviation of the hands with flexion contractures, skin dimple at metacarpophalangeal (MCP) joints, and deformities of fingers (►Fig. 3B). She had flexion contractures of the feet and short toes with hypoplastic toenails. Wrists radiographs revealed the absence of carpal and proximal metacarpal bones (►Fig. 4), and radiographs of both feet revealed metatarsophalangeal joint deformities (►Fig. 5) which are classic findings of MCTO. Based on her radiographic examination, coupled with her son's clinical findings, *MAFB* gene sequencing was ordered on her son and confirmed the family's diagnosis. There were no other family members with a history and/or abnormal physical features suggestive of MCTO. Her renal finding is not available.

Discussion

We report two patients, a 7.5-year-old boy and his affected mother, with a clinical diagnosis of MCTO molecularly

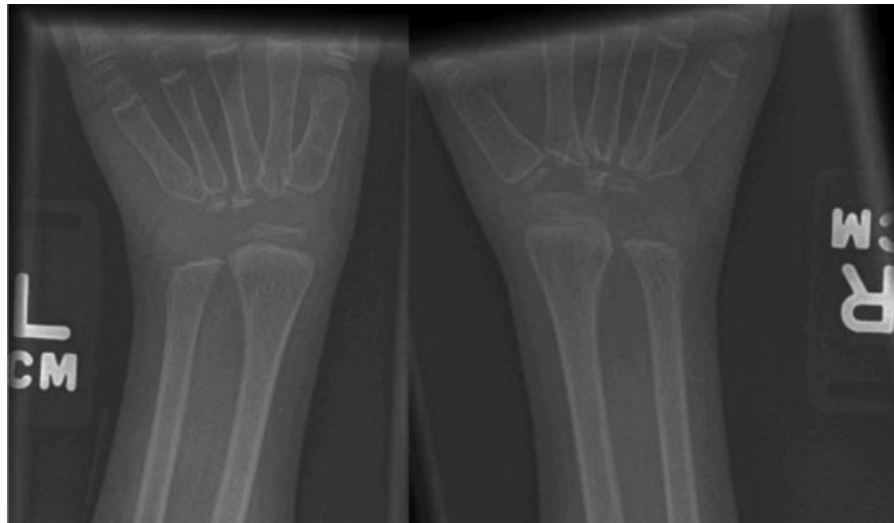


Fig. 2 X-ray of both wrists of our patient at 6 years of age showed severe deficiency of ossified carpal bones with only small portions of the distal row of carpal bone being visible, and erosive changes in the distal radial epiphysis bilaterally. Deformities of the proximal ends of the metacarpals were noted.

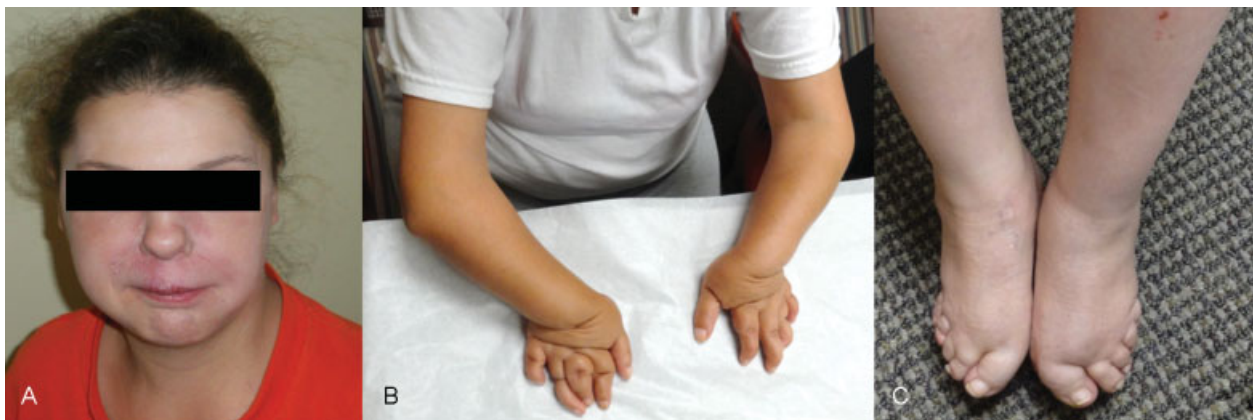

Fig. 3 (A) Anteroposterior view of the patient's mother at age 33 showing hypertelorism, triangular facies, bulbous nose, hypoplastic nares, prominent columella, micrognathia, and chin dimple; (B) View of both hands of the same patient showing deformities and ulnar deviation of both wrists, elbow deformities, skin dimple at metacarpophalangeal joints, and deformities of fingers; (C) View of both feet of the same patient showing bilateral deformities in both feet and toes.

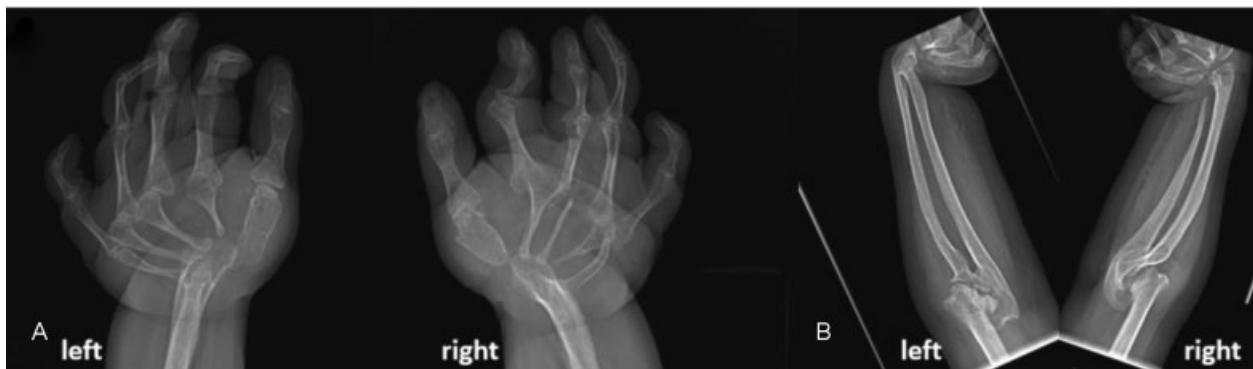

Fig. 4 (A) Hand and forearm radiographs of the mother at age 33 revealed ulnar deviation of the wrists, absent carpal, and proximal metacarpal bones; proximal metacarpal bones are eroded and tapered; interphalangeal joints are distorted; (B) Elbow radiographs of the same patient revealed deformities.

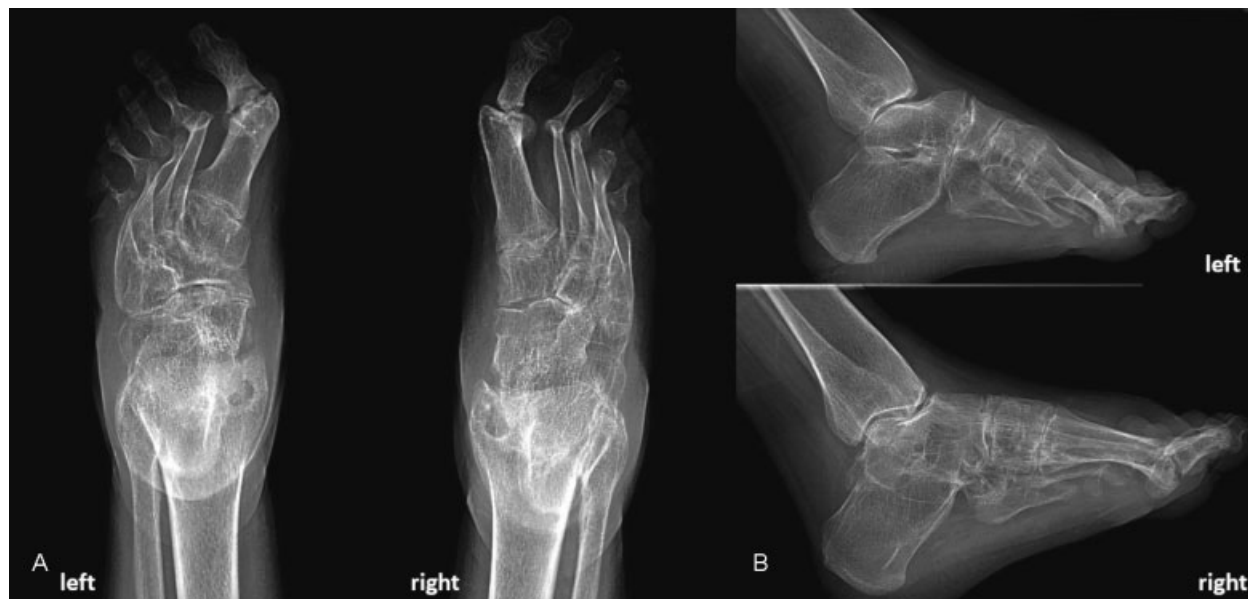

Fig. 5 Anteroposterior (A) and lateral (B) view of both feet revealed marked osteolysis, dysplastic changes, and narrowed joint space of tarsal bones.

confirmed through the identification of an *MAFB* gene mutation in the proband. The proband's mother showed classic clinical characteristics of MCTO, such as joint pain in the wrists and feet with radiographs revealing carpal and tarsal osteolysis. In addition to the classic clinical characteristics of MCTO, the proband also developed involvement of the MCP, PIP, and distal interphalangeal joints with imaging proven synovitis of the wrist, the above-mentioned joints and Boutonnière deformities of the fourth and fifth fingers on the left hand and the fifth finger on the right hand. Both mother and son have a history of learning disabilities.

There are six cases reported that have the same mutation as our patient. Clinical data are not available in one case.^{2,7} There are no correlations that can be made between these cases and our patients regarding disease severity, age of onset, or renal involvement (–Table 1). The literature notes two cases that present with mother–son segregation of disease, as was found in our cohort, supporting the dominant inheritance of this disorder. Renal involvement in MCTO is variable as two reported cases note no signs of renal involvement; one reports proteinuria at age 14; and another reports an affected mother diagnosed with renal failure, while her son harbors the same mutation but shows no signs of renal involvement at the age of 5.5 years.

The reported ages of onset of the musculoskeletal symptoms seen in MCTO also vary from 0.5 to 15 years.^{1,4,15} This condition is clinically heterogeneous and shows intrafamilial variability and evidence of incomplete penetrance in one family.² In addition to osteolysis of carpal and tarsal bones, other joints can be affected as well, but vary among the subjects. Renal involvement is also common, ranging from mild proteinuria to renal failure requiring renal transplantation. Therefore, no genotype–phenotype correlations have been established at this time.

The proband's MRI revealed synovial enhancement suggestive of concomitant underlying inflammatory process. His joint involvement seemed to progress much slower while receiving TNF- α monoclonal antibody–infliximab therapy and seemed to advance while receiving other biologics: abatacept, pamidronate, and just recently tocilizumab. The positive effect of the monoclonal TNF blocking antibody, infliximab, in this case could be explained by previously reported increased osteoprotegerin (OPG) concentrations in Crohn's disease patients. In addition, Miheller et al reported decrease in serum bone absorption marker β -crosslaps.¹⁶ Increased OPG levels would bind more RANKL on osteoblast/stromal cells thus blocking the RANKL–RANK interaction, leading to inhibition of differentiation of the osteoclast precursor into its mature form. TNF blockade by monoclonal antibodies through increased levels of OPG could substitute, even if only partially, the loss of the negative regulator function of MafB on RANKL-mediated osteoclastogenesis in MCTO patients possibly slowing down or stopping disease progression. Further studies including randomized trials might be necessary to confirm this effect.

Multicentric carpotarsal osteolysis is a rare genetic condition and its prevalence has not yet been established. Due to the musculoskeletal presentation at onset, it can be misdiagnosed for other orthopedic or rheumatologic conditions. Making the right diagnosis early on can lead to appropriate management and counseling. We report two patients, mother and son, with a mutation in a highly conserved region of the *MAFB* gene which continues to support the previous studies in genetic homogeneity of this disease.

Conflict of Interest
None.

References

- 1 Mehawej C, Courcet JB, Baujat G, et al. The identification of MAFB mutations in eight patients with multicentric carpo-tarsal osteolysis supports genetic homogeneity but clinical variability. *Am J Med Genet A* 2013;161A(12):3023–3029
- 2 Zankl A, Duncan EL, Leo PJ, et al. Multicentric carpotarsal osteolysis is caused by mutations clustering in the amino-terminal transcriptional activation domain of MAFB. *Am J Hum Genet* 2014;94(04):643
- 3 Kim K, Kim JH, Lee J, et al. MafB negatively regulates RANKL-mediated osteoclast differentiation. *Blood* 2007;109(08):3253–3259
- 4 Shinohara O, Kubota C, Kimura M, Nishimura G, Takahashi S. Essential osteolysis associated with nephropathy, corneal opacity, and pulmonary stenosis. *Am J Med Genet* 1991;41(04):482–486
- 5 Moriguchi T, Hamada M, Morito N, et al. MafB is essential for renal development and F4/80 expression in macrophages. *Mol Cell Biol* 2006;26(15):5715–5727
- 6 Vichi GF, Falcini F, Pierattelli M, Jenuso R, Ceruso M. Case report 401: idiopathic carpal/tarsal osteolysis (ICTO) associated with nephropathy. *Skeletal Radiol* 1986;15(08):665–671
- 7 Mumm S, Huskey M, Duan S, et al. Multicentric carpotarsal osteolysis syndrome is caused by only a few domain-specific mutations in MAFB, a negative regulator of RANKL-induced osteoclastogenesis. *Am J Med Genet A* 2014;164A(09):2287–2293
- 8 Bennett WM, Houghton DC, Beals RC. Nephropathy of idiopathic multicentric osteolysis. *Nephron* 1980;25(03):134–138
- 9 Lagier R, Rutishauser E. Osteoarticular changes in a case of essential osteolysis; an anatomical and radiological study. *J Bone Joint Surg Br* 1965;47:339–353
- 10 Connor A, Highton J, Hung NA, Dunbar J, MacGinley R, Walker R. Multicentric carpal-tarsal osteolysis with nephropathy treated successfully with cyclosporine A: a case report and literature review. *Am J Kidney Dis* 2007;50(04):649–654
- 11 Malecha MA, Wilroy RS Jr. Bilateral corneal opacities associated with idiopathic multicentric osteolysis. *Cornea* 2003;22(04):377–378
- 12 Pai GS, Macpherson RI. Idiopathic multicentric osteolysis: report of two new cases and a review of the literature. *Am J Med Genet* 1988;29(04):929–936
- 13 Dworschak GC, Draaken M, Hilger A, Born M, Reutter H, Ludwig M. An incompletely penetrant novel MAFB (p.Ser56Phe) variant in autosomal dominant multicentric carpotarsal osteolysis syndrome. *Int J Mol Med* 2013;32(01):174–178
- 14 Sun K, Barlow B, Malik F, Inglis A, Figgie M, Goodman S. Total hip arthroplasty in a patient with multicentric carpotarsal osteolysis: a case report. *HSS J* 2016;12(02):177–181
- 15 Whyte MP, Murphy WA, Kleerekoper M, Teitelbaum SL, Avioli LV. Idiopathic multicentric osteolysis. Report of an affected father and son. *Arthritis Rheum* 1978;21(03):367–376
- 16 Miheller P, Muzes G, Rácz K, et al. Changes of OPG and RANKL concentrations in Crohn's disease after infliximab therapy. *Inflamm Bowel Dis* 2007;13(11):1379–1384